

Miss Shaikha Amgad Mohammed

Age -8 Years

Sex- Female

Shaikha resides in Yemen. She has a joint family having many family members with a poor socio-economic status. She is the eldest sister among 4 siblings residing with parents and grandparents. She is an innocent child like any other small girl of her age with an ever smiling face. Pregnancy of her mother was uneventful at the time of delivery she had prolonged labour .Because of prolonged labour the baby suffered from hypoxia due to her mother's ill health. Ventilator support was given immediately and was put on anti-seizure medication. Since then she faced quite alot of difficulties. She came to India with the hope of getting better and came under INAMDAR MULTISPECIALITY HOSPITAL'S expertise care.



SHAIKHA

During her course in she underwent thorough physical assessment.

Problem encountered are

She is a case of Diplegic cerebral palsy.

- ✿ Having “w” sitting position.
- ✿ She is unable to walk and wheel chaired.

Name of the surgical procedure

Bilateral Femoral Osteotomy Plating

Bilateral BOTOX for Hamstring and Tendo Achillis

Post-operatively

Patient had their lower limb immobilized by a splint with

90° flexion for a 3-week interval,

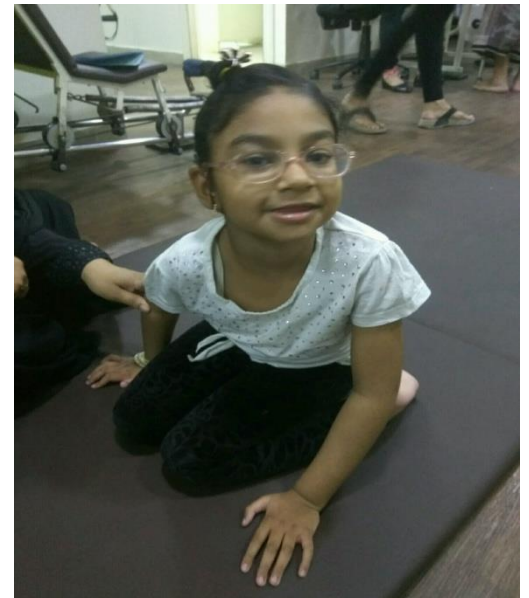
Success of the surgery

Flexion of the knee is reduce


Post operative physiotherapy

Day-1

- Passive range of motion exercise.
- Respiratory exercise.
- Maintains of the joint range exercise.



W Sitting Position



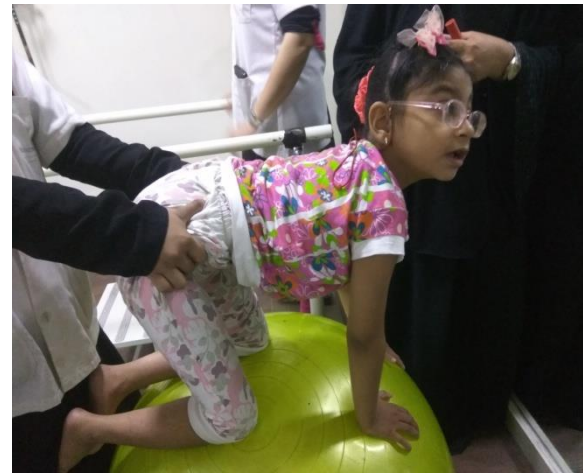Crunches

Day 2 – 2 weeks

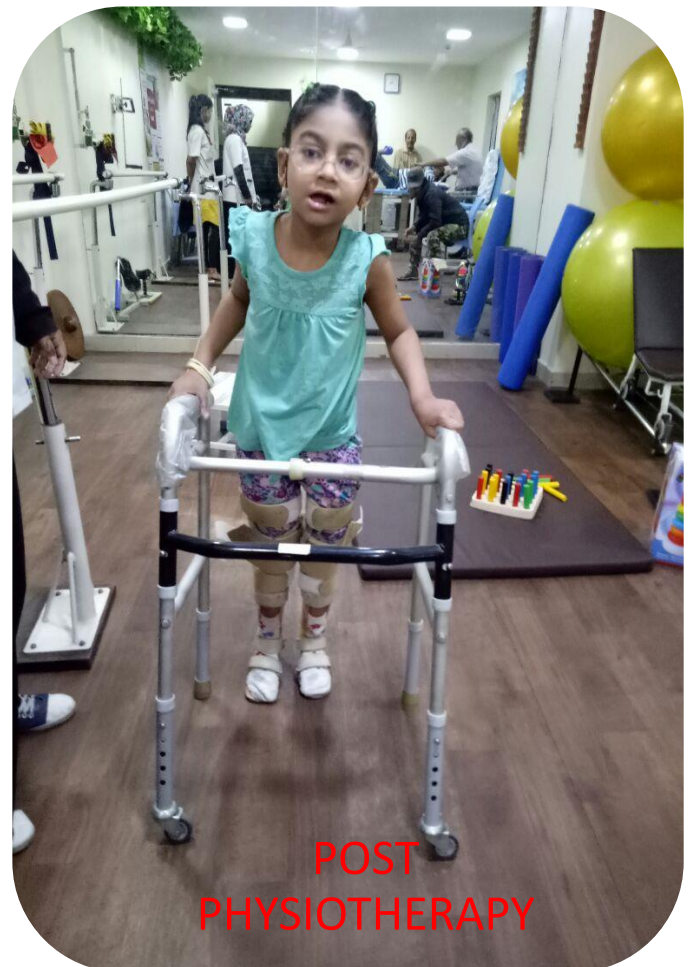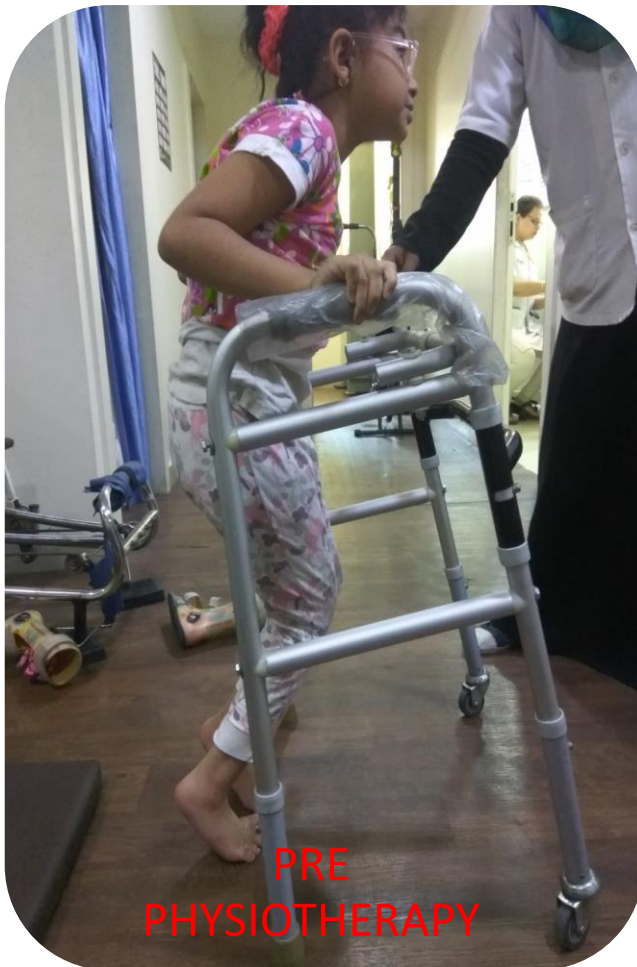- Flexibility exercise
- Maintain full joint range and muscle length of the affected limb.
- Stretching of the hamstring and quadriceps muscle exercise

2 week-6 Months

- Gait re-education.
- Balance board used for improving his balance.
- Various reach and activities in standing for trunk control.
- Encourage return to full function



Physioball Exercise



Now, she is able to walk with the help of the splints and walker.